



**Name:** Ian Cameron  
**Qualifications:** BVM&S BSc (Open) CertEM (StudMed) MRCVS  
**Year of Qualification:** 1999  
**Main interests:** I qualified from The Royal (Dick) School of Veterinary Studies in Edinburgh in 1999 and spent two years in mixed practice in Malpas, Cheshire. In 2001, I moved to RosSDale & Partners in Newmarket to undertake an 18 month internship, based at RosSDales Equine Hospital and Diagnostic Centre. Following this, I moved to the ambulatory side of the practice, concentrating primarily on stud work, which included a breeding season based at Windsor Park Stud in New Zealand. I obtained my Certificate in Equine Stud Medicine in 2007 and also hold a post-graduate degree in philosophy and information technology, through the Open University. I became a partner in 2008 and am responsible for stud farm work, youngstock management and Thoroughbred sales. Outside of work, I am married to Lucy and we have twin boys, aged 8 months. I enjoy skiing and clay-pigeon shooting, although currently my main pastime is childcare!

# REPRODUCTIVE DIGITAL ULTRASOUND IMAGING

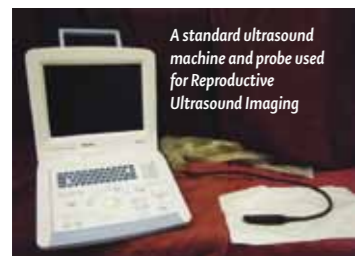
Since the 1980s, the use of ultrasonography to assess the reproductive tract of the mare has revolutionised the understanding of mare reproductive physiology.

The clinician is able to assess reproductive tract health, ovarian activity, diagnose and monitor pregnancy. This allows accurate timing of mating or insemination and, in conjunction with other diagnostic procedures, allows the clinician to assess the requirement for additional treatments. This has in turn led to marked increases in reproductive efficiency and has facilitated the progress of procedures such as artificial insemination and embryo transfer.

## How it works

Ultrasound machines have probes that contain a transducer (a sensor which converts one form of energy to another), which converts the electrical pulses produced from the ultrasound machine into vibrations - sound waves outside the range that we can hear.

Sound waves have the ability to bounce off structures to form an echo, just as you hear an echo if you make a noise in an enclosed area. They travel into the body and reflect



A standard ultrasound machine and probe used for Reproductive Ultrasound Imaging

off tissues, specifically from tissue interfaces of different densities. The transducer detects some of the sound waves as they reverberate back, converting them into electrical pulses, which are then read by the machine and transformed into an image. The intensity of the echo is dependent on the tissue density at the interface of the structure involved. This means that when an ultrasound wave hits bone, the difference in tissue impedance is so great that the majority of the sound waves are reflected, forming a bright white line on the ultrasound screen. In structures with less impedance, some sound waves will progress and some will be reflected, so forming different shades of grey on the screen. Fluid has low levels of impedance so will show up as nearly black, while structures such as ovaries or a uterus will show up as shades of grey, revealing their internal structures. The experienced clinician can then use ultrasound images to help make decisions

on management of the mare at that time.

## Patient Preparation

It is imperative that safety of the operator, handler and mare are considered during a reproductive ultrasound examination. Restraint of a mare in stocks is commonly used and most mares will tolerate this well. Some more fractious mares may need to be

twitched or sedated. If stocks are not available then it is possible, although less safe and satisfactory, to perform the examination around a door post. Either way, it is important that the clinician is able to reach the mare and operate the scanner easily and safely in a relaxed manner, allowing concentration on the images.



A mare being examined in the stocks using an ultrasound scanner.

The mare's tail should be bandaged and held out the way. The clinician should evacuate the rectum of faeces and palpate the ovaries and uterus. The transducer is then introduced into the rectum, (transrectal ultrasonography), ensuring that undue pressure is avoided as this could rupture the rectum wall - a usually fatal injury. Once in place, the transducer can be placed above the reproductive tract and scanning of the ovaries and uterus can commence.

Later in pregnancy, it is possible to image the foetus through the mare's abdominal wall (transabdominal ultrasonography).

## Benefits of Reproductive Ultrasonography

### Predicting ovulation

Ovulation is the moment that the egg is released from the ovary. An egg is present within a fluid filled structure called a follicle, which develops in the ovary. The follicle will collapse, releasing the egg and forming a corpus luteum, which produces the hormone progesterone. The egg then

travels along the fallopian tube, which is a small tube connecting the ovary to the uterus. If fertilisation of the egg occurs (in the fallopian tube), this will develop to form an embryo, which will pass on through the fallopian tube and enter the uterus about 5 days after fertilisation.

The clinician will perform repeated scans on the mare to assess the size and texture of the follicles. Follicles that are over 40mm and palpably softening are likely to ovulate within 24-48 hours. In conjunction with the use of agents such as an LH (luteinising hormone) injection, timing of ovulation can be forecast with reasonable accuracy.

To optimise the chances of successful fertilisation, it is imperative that mating or insemination takes place close to ovulation. Natural service allows the greatest longevity of semen. Artificial insemination with chilled and frozen semen requires more accurate synchronisation of ovulation and insemination.

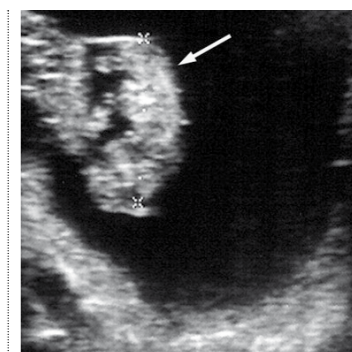
### Monitoring reproductive tract health

Abnormalities of the reproductive tract can

be diagnosed using ultrasonography. Ovarian abnormalities such as Granulosa Cell Tumours or anovulatory follicles can be imaged and assessed. Uterine abnormalities such as endometrial cysts or excessive intra-uterine fluid may be detected. Some mares may develop persistent post-breeding or post-insemination endometritis (inflammation of the uterus), which can be detected by scanning the mare a minimum of 6 hours after insemination, and if present, can be treated.

### Diagnosing and monitoring pregnancy

Early pregnancy diagnosis helps to improve breeding efficiency by allowing preparation for repeated mating/insemination if the mare is not in foal, and detection of twin pregnancies. Twin pregnancies carry a very poor prognosis for birth of viable foals, so one conceptus (embryo) is manually crushed to allow the other to have an increased chance of survival. It is advisable to monitor pregnancies carefully until at least 42 days post insemination. Following this, the mare is unlikely to return to



A 42 day scan image showing the 'pregnancy sac' (black area) within the uterus. The foetus can be seen as the grey area in the centre of the pregnancy sac (arrowed).

oestrus, so cannot be covered again if she loses her pregnancy. Between 60 and 70 days, the gender of the foetus can be identified, although this examination requires an excellent quality scanner and an experienced operator to be accurate. Later in pregnancy, some abnormalities of the foetus and the placenta can be examined by a combination of transabdominal and transrectal ultrasound scans.

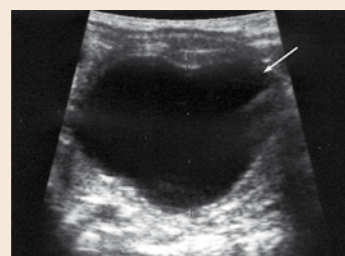## Conclusion

Use of reproductive ultrasound imaging is widespread and probably the most common use of ultrasonography in equine practice. It has made a huge difference to breeding efficiency and is likely to remain the crucial imaging technique in the management of reproductive cases.

## A week in brief...

### Monday

The week starts with a routine stud round, where I check any newborn foals, check mares after foaling and examine mares that are due to be covered or for pregnancy diagnosis. One mare called Poppy was showing signs of oestrus and had a large, slightly soft follicle on her right ovary. Cervical swabs were taken and she is booked in for a cover on Wednesday with the stallion she is due to visit.



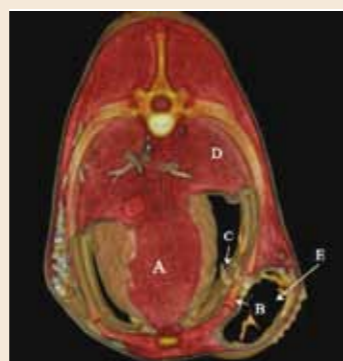A large follicle present on the ovary (arrowed), which appears to be near to ovulation.

### Tuesday

Through the night, I attended a sick foal which was having difficulty standing following a complicated foaling. Pain was noted during palpation of the ribs, and the foal was unable to stand unaided and had a poor suck reflex. The foal's ribs were scanned and there was a

suggestion of fractured ribs. Colostrum was administered by stomach tube, and the foal was referred into the foal unit at RosSDales Equine Hospital for further assessment and treatment.

During the day the foal was stabilised, but remained unable to stand. A CT scan was performed, which provided excellent quality images, allowing us to make an accurate assessment of the extent of damage to the ribs. Following careful discussion with the stud



A CT scan of a 1 day old foal with a fractured rib at the level of the heart (A). The image shows the fracture fragment (B) has pierced the chest cavity (C). The lungs are labelled (D) and there is a haematoma present under the skin (E).

owner, it was decided to surgically fixate the broken ribs, a procedure which was performed by the surgical team later that day. Thankfully the foal made it through the surgery and will now require intensive post-operative management by our specialist veterinary and nursing teams.

Swab results from Poppy suggested that there was no evidence of endometritis (inflammation of the uterus), so she is a good candidate for cover tomorrow, as planned.

### Wednesday

Poppy receives an injection of LH (Luteinising Hormone) prior to cover to encourage ovulation. During stud rounds, one mare is scanned 16 days after cover and is found to be in foal. She has a perfectly round conceptus in the right horn of her uterus. There is general feeling of relief felt by both the vet and stud groom, as she has previously been a difficult mare to get in foal. We will re-scan her in 5 days.

The team in the hospital are making satisfactory progress with the foal with fractured ribs. He remains unable to stand but his demeanour is somewhat better than prior to surgery.

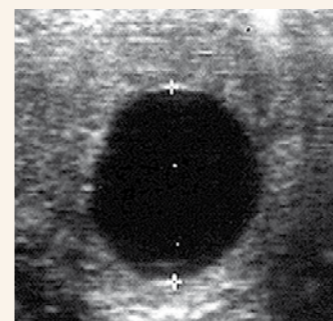
### Thursday

I have been asked to examine a stallion in order to carry out a routine check on his semen quality. He is known to have good fertility, but it is important that we are satisfied that all is well for the breeding season. The stallion covers a mare that morning and we collect a small amount of semen as he dismounts. Immediately, this sample is checked under the microscope and is found to have good numbers of sperm of

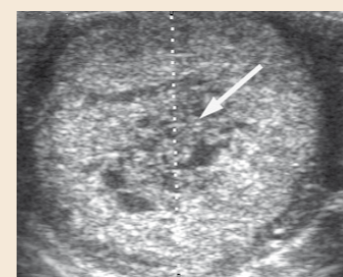
good motility, so we remain satisfied that the stallion is being managed correctly. The foal in the hospital was able to stand unaided (if a little wobbly!) today. This represents great progress.

### Friday

Poppy is scanned today following mating on Wednesday. She has a corpus luteum on the right ovary, so ovulation has occurred and the egg has been released. There is no fluid in the uterus, so we remain hopeful that she will be pregnant when we scan her in 14 days' time. The foal in the hospital has managed to stand and suck from the mare's udder today. The surgical site is healing well. Hopefully, with continuing careful management, the foal will make a full recovery.



A scan of 16 days' pregnancy. The foetus cannot be seen, but a perfectly round 'pregnancy sac' is visible within the uterus.



A corpus luteum present on the ovary (arrowed), confirming ovulation has taken place.



### RosSDales Equine Hospital & Diagnostic Centre

(All horse admissions)  
 Cotton End Road, Exning, Newmarket, Suffolk CB8 7NN.

Tel: 01638 577754 (Office hours) 01638 663150 (24 hours)

Email: [hospital@rossdales.com](mailto:hospital@rossdales.com)

### Beaufort Cottage Stables

(Ambulatory Practice, Pharmacy and Accounts)

High Street, Newmarket, Suffolk CB8 8JS. Tel: 01638 663150 (24 hours)

Email: [practice@rossdales.com](mailto:practice@rossdales.com)

### Beaufort Cottage Laboratories

(Laboratory samples and aborted foeti for postmortem examinations)

High Street, Newmarket, Suffolk CB8 8JS. Tel: 01638 663017 (Office hours)

01638 663150 (24 hours) Email: [laboratory@rossdales.com](mailto:laboratory@rossdales.com)